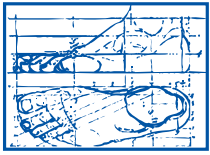


foot facts



**ALEXANDRIA
PODIATRY
ASSOCIATES**

Dr. Jeffrey S. Coster
Dr. Jeffrey L. Graziano
Dr. Joonhyun Yoon
Dr. Monique Rolle
703-379-0700 (office)

THE ROLE OF FOOT X-RAYS

The cardinal rule of professional health care is DIAGNOSIS before treatment. Your podiatrist often requests a group of foot x-rays to insure a complete understanding of your foot problems.

Important Aid in Diagnosis

Each foot is made up of 26 bones - one - fourth of ALL the body bones are in your two feet! Almost any disease or condition that might affect the bony system elsewhere can also occur in the foot. Other structures such as tendons, ligaments, blood vessels, etc., must also be considered. These, plus the severe mechanical strain of locomotion affect the various foot structures. In order to find the basic cause of many foot complaints, an x-ray study may be necessary in addition to the clinical examination.

Foot Injuries and X-Ray

There is not such a thing as "a minor foot injury." Many times if bones are not broken they are "cracked" or "chipped" from seemingly minor accidents. A sprained ankle is not properly treated by an inexpensive ankle support. An x-ray may reveal if the structures supporting the joint have been torn allowing the bones to separate or slip out of place. By knowing immediately, your podiatrist can treat effectively and limit the pain and swelling that could sometimes last for months.


The Child and Foot X-Ray

Fortunately today we see very little underdevelopment of bone in children. When a clinical evaluation suggests this problem, x-ray studies should be made. The bones of the feet are not completely ossified (formed) until 18 - 20 years of age. Night leg cramps, pigeon toes, knock-knees, frequent falling and sprained ankles, rolling to the inner or outer side of the foot or shoes or many other signs may be due to a mechanically faulty child's foot. Promiscuous use of "arch supports" or "orthopedic shoes" may delay correct diagnosis and proper care. When indicated from the findings, x-ray films should be studied and then the proper treatment instituted.

Bony Growths of the Foot

Hidden by the shoe are a horde of "humps" and "bumps" of the feet. The most obvious and deforming is a bunion. All heel complaints should have the benefit of x-ray studies as this is

foot facts



**ALEXANDRIA
PODIATRY
ASSOCIATES**

**Dr. Jeffrey S. Coster
Dr. Jeffrey L. Graziano
Dr. Joonhyun Yoon
Dr. Monique Rolle
703-379-0700 (office)**

THE ROLE OF FOOT X-RAYS

the only method to prove the presence or absence of spur formations. Growths under the nails are also common. Sometimes nature has formed accessory (extra) bones which become painful from irritation. Following a clinical diagnosis, x-ray confirmation may be necessary for effective treatment of these and many other foot conditions.

Arthritis and X-Ray

No other test is as important as x-ray to either “rule out” or determine the kind of arthritis present. There are two major types of arthritis. Nowhere in the body is as much “wear and tear” (osteo) arthritis seen as in the joints of the feet. The “crippler” (rheumatoid) is most often seen in the toes and fingers first. Complete x-ray studies by the podiatrist are necessary for most patients complaining of painful feet.

Foot Surgery and X-Ray

Your podiatrist may find surgery to be the solution for your foot problem. Bone abnormalities and such conditions as cysts, masses such as tumors, sinuses, shortened tendons causing hammer toes, etc., all need the benefit of x-ray prior to the corrective procedure.

By training your podiatrist is qualified to interpret foot x-rays. In addition he is aware of the precautions to be taken to protect you from the undesirable aspects of radiation.